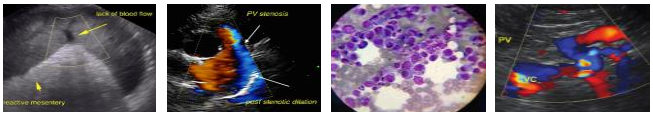

SonoPath.com
1-800-838-4268 info@sonopath.com

DATE

4/19/23

PERFORMED BY:

Kelly Vazquez

INTERPRETED BY

Keith Blass, DVM, MS, DACVIM (Cardiology)

PATIENT

Dexter Cunningham

SPECIES

Feline

BREED

Sphynx

SEX

MI

AGE

11 mo

WEIGHT

8.1 lb

HOSPITAL NAME

Ramapo Valley AH

REFERRING VET

Dr. Katara

PRESENTING CLINICAL SIGNS

History: Diagnosed with mitral valve dysplasia in October 2022. Receiving atenolol 6.25 mg BID and pimobendan 1.25 mg BID.

ECHOCARDIOGRAPHIC FINDINGS

2D, M-mode, and Doppler study.

There is mild left atrial dilation. The anterior mitral valve leaflet is elongated, and there is systolic anterior motion of the leaflet creating dynamic obstruction to flow in the left ventricular outflow tract, with mild secondary mitral regurgitation. There is mild symmetrical left ventricular hypertrophy. Left ventricular internal dimensions are normal. Left ventricular systolic function is hyperdynamic. The aorta and aortic valve are normal. Right atrial and right ventricular dimensions are normal. The tricuspid valve is normal. The pulmonary artery and pulmonic valve are normal. No shunting lesions are visualized. No pericardial effusion or cardiac masses are seen.

LA/Ao – 1.60 (prev 1.45)
IVSd – 6.3 mm (prev. 6.2 mm)
LVPWd – 6.0 mm (prev. 6.1 mm)
LVIDd – 16.0 mm (prev. 14.9 mm)
LVIDs –6.2 mm (prev. 5.7 mm)
FS – 61.3% (prev. 61.7%)
RA – 11.6 mm (prev. 11.0 mm)
LVOT – 5.27 m/s
RVOT – 1.50 m/s (prev. 1.24 m/s)

ASSESSMENT/RECOMMENDATIONS

Mitral valve dysplasia (MVD)

This examination demonstrates mild progression of Dexter's cardiac disease over the past 6 months, as he now has mild dilation of his left atrium. Given this, Dexter's current risk for the development of congestive heart failure and/or thromboembolic disease has mildly increased, and careful monitoring for clinical signs associated with these conditions is recommended.

Continued use of atenolol is recommended at this time, as is therapy with clopidogrel (18.75 mg BID). Pimobendan is not recommended at this stage of disease, as it could worsen Dexter's SAM and negate the effects of atenolol on the SAM.

A recheck echocardiogram is recommended in 6-9 months, sooner if new clinical signs compatible with cardiac dysfunction (ex. labored breathing, collapse, limb paralysis) develop.

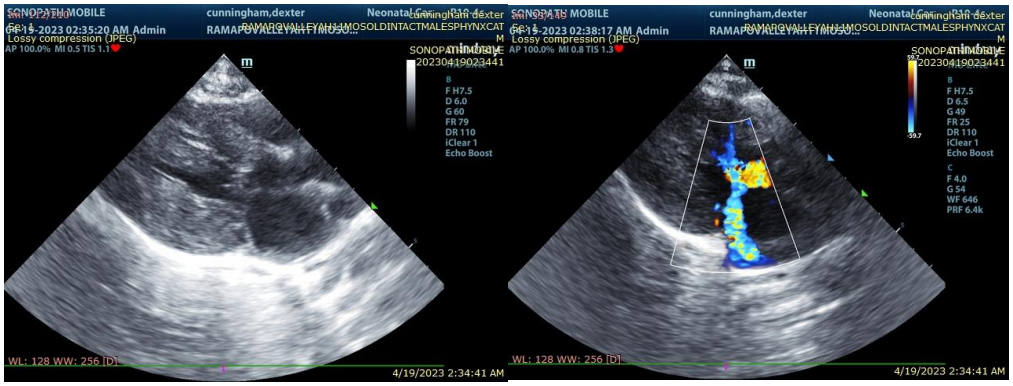

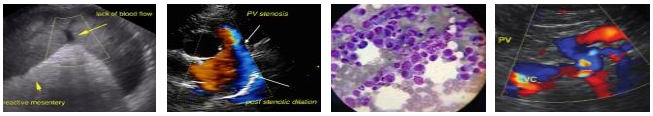

SonoPath.com
1-800-838-4268 info@sonopath.com

DATE

4/19/23

PERFORMED BY:

Kelly Vazquez

INTERPRETED BY

Keith Blass, DVM, MS, DACVIM (Cardiology)

PATIENT

Dexter Cunningham

SPECIES

Feline

BREED

Sphynx

SEX

MI

AGE

11 mo

WEIGHT

8.1 lb

HOSPITAL NAME

Ramapo Valley AH

REFERRING VET

Dr. Katara

The information and recommendations provided are based on the images presented by the referring veterinarian. No evaluation can be communicated regarding pathology that was not visible in the image/video clips provided.

Thank you for this referral. If the clinical or image interpretation does not parallel your findings or if I can be of any further assistance please contact me.

Keith Blass, DVM, MS, DACVIM (Cardiology)
KeithBlass@gmail.com
631-804-5754